

## Role of Balloon-Expandable Stents in Intracranial Atherosclerotic Disease in a Series of 182 Patients

Anand Alurkar, Lakshmi Sudha Prasanna Karanam, Sagar Oak, Suresh Nayak and Sandeep Sorte

*Stroke*. 2013;44:2000-2003; originally published online May 21, 2013;

doi: 10.1161/STROKEAHA.113.001446

*Stroke* is published by the American Heart Association, 7272 Greenville Avenue, Dallas, TX 75231

Copyright © 2013 American Heart Association, Inc. All rights reserved.

Print ISSN: 0039-2499. Online ISSN: 1524-4628

The online version of this article, along with updated information and services, is located on the World Wide Web at:

<http://stroke.ahajournals.org/content/44/7/2000>

Data Supplement (unedited) at:

<http://stroke.ahajournals.org/content/suppl/2013/05/21/STROKEAHA.113.001446.DC1.html>

**Permissions:** Requests for permissions to reproduce figures, tables, or portions of articles originally published in *Stroke* can be obtained via RightsLink, a service of the Copyright Clearance Center, not the Editorial Office. Once the online version of the published article for which permission is being requested is located, click Request Permissions in the middle column of the Web page under Services. Further information about this process is available in the [Permissions and Rights Question and Answer](#) document.

**Reprints:** Information about reprints can be found online at:

<http://www.lww.com/reprints>

**Subscriptions:** Information about subscribing to *Stroke* is online at:

<http://stroke.ahajournals.org/subscriptions/>

# Role of Balloon-Expandable Stents in Intracranial Atherosclerotic Disease in a Series of 182 Patients

Anand Alurkar, MD; Lakshmi Sudha Prasanna Karanam, MD; Sagar Oak, MD; Suresh Nayak, MS; Sandeep Sorte, MS

**Background and Purpose**—To demonstrate the safety and efficacy of balloon-expandable intracranial stents in patients with intracranial atherosclerotic lesions (>70% stenosis) who were symptomatic despite being on optimum medical therapy.

**Methods**—Between April 2004 and May 2012, 182 patients underwent intracranial stenting in our institution. All patients had symptoms despite being on optimum medical therapy. Clinical follow-up was done at 1, 3, 6, and 12 months. Angiographic follow-up was done at 1 year in 121 patients.

**Results**—Technical success was achieved in 97.44% of the cases. The incidence of all strokes at 1 month after procedure was 11 (5.64%), of which 2 (1.02%) were major, both related to stent thrombosis not responding to tirofiban, and 9 (4.61%) were minor. Periprocedural minor stroke was seen in 9 patients. There were 2 deaths in our study (mortality=1.09%).

**Conclusions**—Treatment of intracranial atherosclerotic disease with balloon-expandable intracranial stents is a safe and effective method with acceptable adverse events, especially in patients who failed medical therapy and were symptomatic despite being on optimum medical therapy. (*Stroke*. 2013;44:2000-2003.)

**Key Words:** intracranial stenosis ■ stenting ■ stroke

Intracranial atherosclerosis is a high-risk cause of ischemic stroke. Intracranial atherosclerotic disease accounts for 30% to 50% of strokes in the Asian population.<sup>1</sup> Hence, the impact of this disease is more relevant in the Asian population compared with other ethnicities. In our present study, we evaluated the procedural safety and success of balloon-expandable intracranial stent placement in patients with symptomatic severe lesions (>70% stenosis) who had symptoms despite being on optimum medical therapy.

## Patients and Methods

The present study is a retrospective analysis of patients from a prospectively collected institutional review board–approved database. From April 2004 to May 2012, 182 patients with 195 intracranial atherosclerotic lesions underwent intracranial stenting with balloon-expandable intracranial stents. There were 111 men and 71 women, with age group ranging from 18 to 75 years.

Inclusion criteria for intracranial stent placement were severe (>70% stenosis on digital subtraction angiography) atheromatous lesions and symptomatic despite being on optimum medical therapy (aspirin 150 mg/d and clopidogrel 75 mg with atorvastatin 40 mg/d for at least 1 week). Symptoms were classified as recurrent transient ischemic attacks (TIAs; 136 of 182 patients), recurrent minor strokes (35 of 182 patients), and first TIA or minor stroke with patient already on optimum medical therapy (11 of 182 patients).

Exclusion criteria were <18 or >75 years of age, serum creatinine >221 μmol/L, presence of major stroke with disability, known hypersensitivity to contrast agent, very tortuous anatomy, middle

cerebral artery bifurcation lesions (lesions beyond M1), associated intraluminal thrombus, and extensive associated small vessel disease, especially ostial disease in branches arising from the lesion.

Demographic features, risk factors, and location of the lesion were recorded. Brain MRI was performed on all patients before stent placement. Foci of restricted diffusion, suggestive of acute infarcts on diffusion-weighted imaging, were seen in 63 patients.

Stenting for 2 intracranial lesions (double stenting) was done in 13 Patients. Ten patients had tandem lesions (ICA origin+middle cerebral artery or intracranial ICA in 5 patients and vertebral ostial+intracranial VA or basilar in 5 patients). Stenting was done in the same session (tandem stenting) in the 5 patients with tandem vertebrobasilar lesions. In the 5 patients with ICA origin stenosis and ipsilateral M1 or intracranial lesions, stenting of the proximal lesion was done in the first stage followed by the distal lesion after 2 weeks.

All patients were followed clinically at fortnightly intervals for 1 month, monthly intervals for 6 months, and 3 monthly intervals thereafter. A 1-year follow-up digital subtraction angiogram was advised in all patients but could be done in 121 patients.

Association of 9 variables, ie, age, sex, hypertension, diabetes mellitus, smoking, territory of disease, degree of stenosis (70%–90% versus 90%–99%), type of stent used, and timing of the procedure (whether the procedure was done in first half of the study period or in the later half), was assessed and studied for impact on the various outcome measures.

## Results

Procedural success rate was 97.44% in our study. Technical failure because of the difficulty to negotiate the stent to the target lesion occurred in 2.56% (5 of 195) of the lesions. The

Received March 12, 2013; accepted March 19, 2013.

From the Department of Neurointervention, King Edward Memorial Hospital, Pune, India.

The online-only Data Supplement is available with this article at <http://stroke.ahajournals.org/lookup/suppl/doi:10.1161/STROKEAHA.113.001446/-/DC1>.

Correspondence to Lakshmi Sudha P. Karanam, MD, FINR, Department of Neurointervention, King Edward Memorial Hospital, Pune 411011, India. E-mail [drklsp@gmail.com](mailto:drklsp@gmail.com)

© 2013 American Heart Association, Inc.

Stroke is available at <http://stroke.ahajournals.org>

DOI: 10.1161/STROKEAHA.113.001446

**Table. One-Month Incidence of All Complications**

1. All strokes	11
a. Major strokes because of stent thrombosis and occlusion	2
b. Minor strokes	9
2. Asymptomatic stent thrombosis	3
3. Worsening of azotemia and hemothorax	1
4. Vessel dissection	2
5. SAH because of wire perforation	2
6. Total	19
7. Mortality (patients in 1a and 3)	2

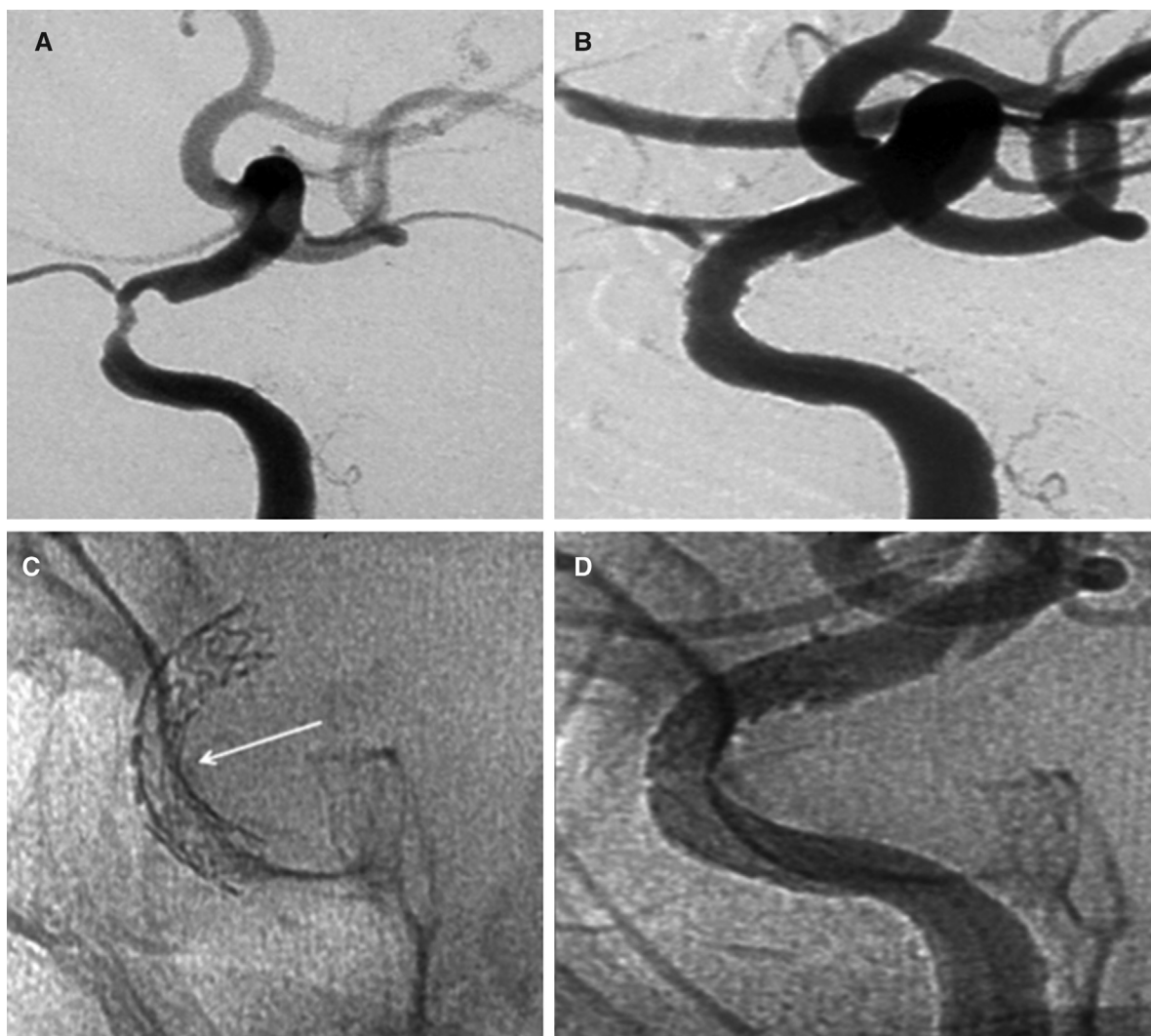SAH indicates subarachnoid hemorrhage.

incidence of all complications  $\leq 1$  month after the procedure was 9.74% (19 of 195 lesions; Table).

All strokes at 1 month were 11 (5.64%), of which 2 (1.02%) were major, both related to stent thrombosis not responding to tirofiban, and 9 (4.61%) were minor. Of the minor strokes, 5 were attributable to perforator occlusion because of the stent and 4 were embolic in the territory of the stented artery. The

mortality at 1 month was 1.09% (2 of 182 patients). One patient died of a major stroke resulting from stent thrombosis and the other due to worsening of azotemia and severe hemothorax. There was acute (during or within 48 hours of the procedure) stent thrombosis in 5 stented lesions (2.56%). Of these, there was major stroke because of the failure to lyse the thrombus in 2 patients, as already mentioned, and 3 were asymptomatic as a result of successful lysis of the thrombus with tirofiban.

The incidence of periprocedural (1 month) complications was 12 of 19 (63.15%) in the first half of our study period (April 2004 to April 2008) and 7 of 19 (36.85%) in the second half (May 2008 to May 2012). The 1-month complication rate in anterior circulation lesions was 8.62% (10 complications in 116 lesions stented), and in posterior circulation lesions, it was 11.39% (9 complications in 79 lesions stented). The incidence of perforator territory stroke was maximum in the basilar artery lesions (4 strokes of the 39 lesions stented; ie, 10.25%). Only 1 perforator territory stroke occurred in all the other lesions put together (1 of the 156 lesions stented; ie, 0.56%).



**Figure 1.** A 40-year-old woman presented with right-sided upper limb weakness. Digital subtraction angiogram showing  $>70\%$  stenosis of the left cavernous ICA segment (A). Endeavor drug-eluting stent was placed across the lesion, and poststent angiogram (B) showed resolution of the stenosis. Control angiogram (C, D) showed patent stent and good antegrade flow through the stent distally.

Recurrent TIA or stroke occurring up to 1-year follow-up in the territory of the stented artery was encountered in 7 patients. Therefore, the 1-year incidence of all strokes or TIAs (including periprocedural) in this study is 18 (9.8%). All these 7 patients underwent a follow-up angiogram. Restenosis, defined as >20% absolute luminal loss, was found in 4 of these patients. All the symptomatic patients were advised to continue dual antiplatelets lifelong (online-only Data Supplement).

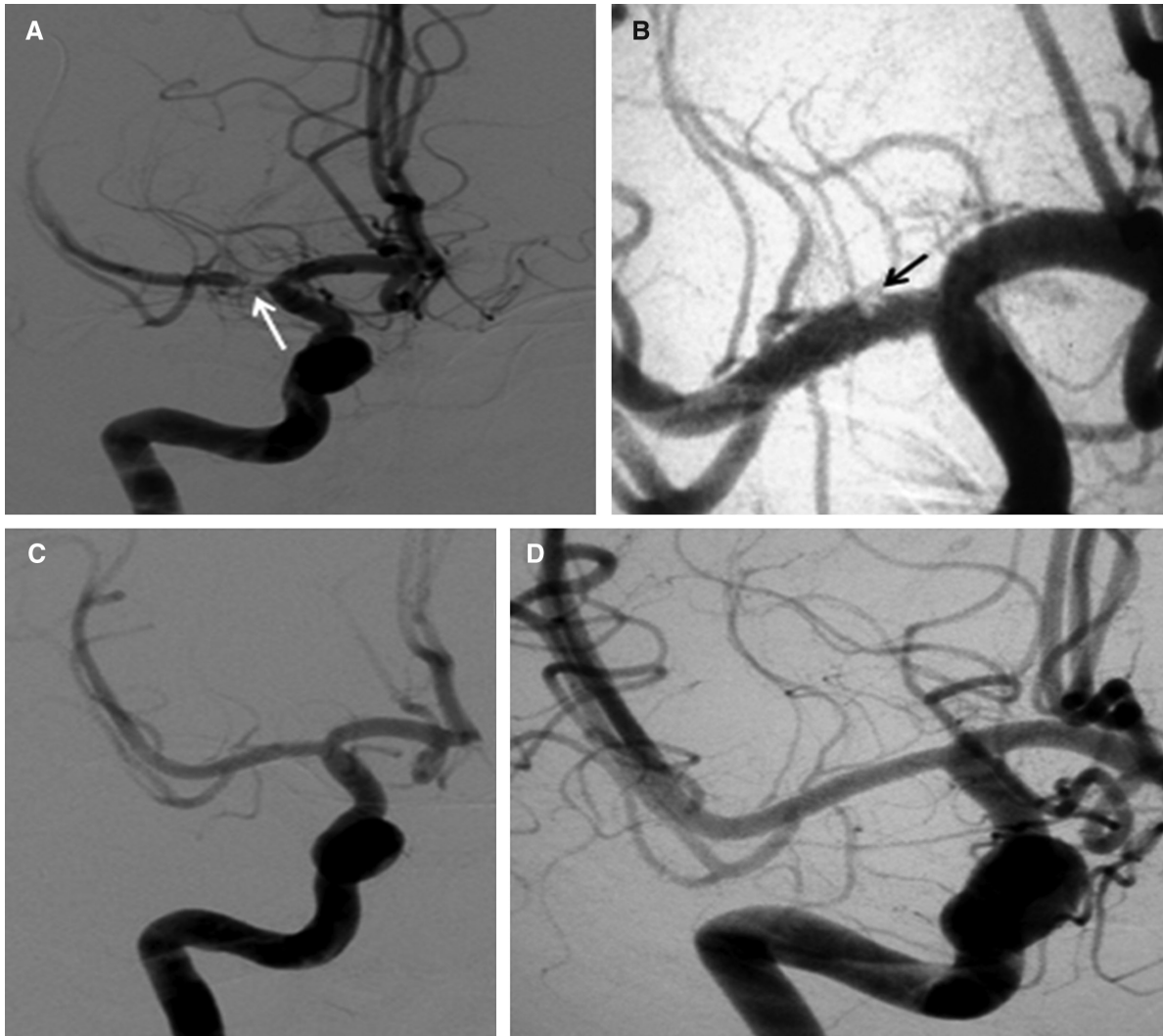
### Discussion

All the patients in our series had severe stenosis, which is described as >70% stenosis, a factor known to be associated with greater risk of stroke.<sup>2</sup> The results of stenting versus aggressive medical management in intracranial stenosis trial were recently published. The 30-day rate of stroke or death in the stenting arm of the SAMMPRIS<sup>3</sup> (Stenting and Aggressive Medical Management for Preventing Recurrent stroke in Intracranial Stenosis) trial was 14.6% compared with 5.8% in the medical management group. We had a 30-day stroke rate

of 5.64% in our series, which is comparable to the early series in the literature.<sup>4-7</sup>

Procedural safety and success because of the rigidity of the device and high inflation pressures were of concern in balloon-expandable stents. In our series, predilation was avoided as far as possible (done only in 14 lesions) to reduce the chances of vessel dissection. Other technical modifications, such as marginal undersizing of the stent, slow optimal inflation of the stent at nominal, and in some cases, even subnominal, pressures and avoidance of postdilation also contributed to the safety of our procedure.

We used both driver (bare metal) and endeavor (drug eluting) stents (Figure 1), with a procedural success rate of 97.44%. Endeavor stent was preferred in long lesions (>5 mm), small target vessels (<2.75 mm), and in relatively younger patients. We did not find any difference in ease of navigating the stent to the target lesion between the driver (bare-metal stent) and endeavor (drug-eluting stent [DES]) groups. Comparatively, limited data are available in the literature on DES.<sup>8-11</sup> To our



**Figure 2.** A 30-year-old man presented with left-sided crescendo transient ischemic attacks. Digital subtraction angiogram showed severe stenosis of the right M1 (A). Poststent angiogram showed evidence of filling defect s/o thrombus within the stent (B). After a bolus of tirofiban, thrombus resolved, and digital subtraction angiogram showed good patent stent across the lesion (C) with improved antegrade flow. Control angiogram after 1 year (D) showed good patency of the stent with no restenosis.

knowledge, ours is one of the largest series in which DES are used in 87 lesions.

Perforator stroke attributable to the compromise of perforating arteries remains a challenge in intracranial atherosclerotic lesions. Perforator stroke occurs as a result of the snow plow effect. Lesions with extensive associated ostial disease were excluded from our series, which is one of the reasons for the low rate of perforator stroke (2.7%) in our series.<sup>12</sup>

In-stent thrombosis is another known complication with the use of intracranial stents. Five patients in our series had acute in-stent thrombosis, of whom 2 did not respond to intra-arterial tirofiban resulting in major strokes. In 3 patients, the thrombus dissolved on administration of tirofiban and there was no neurological deficit on extubation (Figure 2).

In-stent restenosis is defined as >20% absolute luminal loss and is another concern in determining the efficacy of an intracranial stenting procedure. One-year follow-up angiogram was performed in 66% of our patients, and 5.7% (7 lesions) of the lesions showed restenosis. Lack of angiographic follow-up in all patients is one of the limitations in our study, which is likely to underrepresent the rate of restenosis. However, clinical follow-up data are available on all patients, and recurrent TIA or stroke was encountered in 7 patients on follow-up, and 4 of these patients had restenosis on angiogram. In the long-term clinical follow-up (beyond 1 year) none of the patients had any recurrent symptoms in the stented vascular territory.

In their study of DES in 95 patients, Vajda et al<sup>11</sup> described a restenosis rate of 3.8%. Kim et al<sup>13</sup> described their experience in patients with intracranial atherosclerotic disease with >50% stenosis with intracranial stent implantation where endeavor was used in 46 patients with a restenosis rate of 4%. The lower restenosis rate in our series may be partially attributed to the use of DES as well as to the criteria based on which the stent placement was decided.

In the present post-SAMMPRIS era, the results of our study with 97.4% success rate, 5.6% stroke rate at 30-day interval, 9.8% stroke or TIA incidence at 1-year interval, and 5.7% restenosis at 1-year follow-up are encouraging. Debate still continues on the results of the SAMMPRIS trial, on whether the complications in the stenting arm were attributable to device issues, limited experience, poor patient selection, etc.<sup>11,14,15</sup> Intracranial stenting with balloon-expandable intracranial stents is a safe and feasible method and should be considered as a therapeutic option in

selected patients with severe symptomatic intracranial stenosis (>70%) refractory to medical therapy with an acceptable risk to benefit ratio.

## Disclosures

None.

## References

1. Wong LK. Global burden of intracranial atherosclerosis. *Int J Stroke*. 2006;1:158–159.
2. Kasner SE, Chimowitz MI, Lynn MJ, Howlett-Smith H, Barney JS, Vicki SH, et al. Predictors of ischemic stroke in the territory of a symptomatic intracranial arterial stenosis. *Circulation*. 2006;113:555–563.
3. Chimowitz MI, Lynn MJ, Derdeyn CP, Turan TN, Fiorella D, Lane BF, et al; SAMMPRIS Trial Investigators. Stenting versus aggressive medical therapy for intracranial arterial stenosis. *N Engl J Med*. 2011;365:993–1003.
4. SSVLVA Study Investigators. Stenting of symptomatic atherosclerotic lesions in the vertebral/or intracranial arteries (SSVLVA): study results. *Stroke*. 2004;35:1388–1392.
5. Mazighi M, Yadav JS, Abou-Chebl A. Durability of endovascular therapy for symptomatic intracranial atherosclerosis. *Stroke*. 2008;39:1766–1769.
6. Yu W, Smith WS, Singh V, Ko NU, Cullen SP, Dowd CF, et al. Long-term outcome of endovascular stenting for symptomatic basilar artery stenosis. *Neurology*. 2005;64:1055–1057.
7. Jiang WJ, Wang YJ, Du B, Wang SX, Wang GH, Jin M, et al. Stenting of symptomatic M1 stenosis of middle cerebral artery: an initial experience of 40 patients. *Stroke*. 2004;35:1375–1380.
8. Abou-Chebl A, Bashir Q, Yadav JS. Drug-eluting stents for the treatment of intracranial atherosclerosis: initial experience and midterm angiographic follow-up. *Stroke*. 2005;36:e165–e168.
9. Gupta R, Al-Ali F, Thomas AJ, Horowitz MB, Barrow T, Vora NA, et al. Safety, feasibility, and short-term follow-up of drug-eluting stent placement in the intracranial and extracranial circulation. *Stroke*. 2006;37:2562–2566.
10. Fields JD, Petersen BD, Lutsep HL, Nesbit GM, Liu KC, Dogan A, et al. Drug eluting stents for symptomatic intracranial and vertebral artery stenosis. *Interv Neuroradiol*. 2011;17:241–247.
11. Vajda Z, Aguilar M, Göhringer T, Horváth-Rizea D, Bázner H, Henkes H. Treatment of intracranial atherosclerotic disease with a balloon-expandable paclitaxel eluting stent: procedural safety, efficacy and midterm patency. *Clin Neuroradiol*. 2012;22:227–233.
12. Jiang WJ, Srivastava T, Gao F, Du B, Dong KH, Xu XT. Perforator stroke after elective stenting of symptomatic intracranial stenosis. *Neurology*. 2006;66:1868–1872.
13. Kim KS, Hwang DH, Ko YH, Kang IW, Lee ES, Han YM, et al. Usefulness of stent implantation for treatment of intracranial atherosclerotic stenoses. *Neurointervention*. 2012;7:27–33.
14. Henkes H, Bázner H, Nelson PK. Comment on: stenting versus aggressive medical therapy for intracranial arterial stenosis. *Clin Neuroradiol*. 2011; 21:257–259.
15. Michael P, Marks S. There a future for endovascular treatment of intracranial atherosclerotic disease after stenting and aggressive medical management for preventing recurrent stroke and intracranial stenosis (SAMMPRIS)? *Stroke*. 2012;43:580–584.

## Statistics:

A multivariate analysis by logistic regression routine was carried out using ‘NCSS – PASS’ 2004 version. All results are reported as OR (Odds ratio) with 95% confidence intervals. A ‘P’ value of < 0.05 was considered statistically significant. (Tables IV to VIII)

### **One month incidence of all complications: (Table IV in supplement)**

Higher degree (>90%) of stenosis was the single most important factor associated with increased incidence of all complications in one month periprocedural period with a p value of 0.04. Diabetes and timing of the procedure in the first half of the study were the other variables which impacted this outcome but barely missed statistical significance with p values of 0.052 and 0.054 respectively.

### **One month incidence of Major stroke: (Table V in supplement)**

The presence of Hypertension, smoking, posterior circulation disease, bare metal stent and procedures in first half of the study were found to be associated with the increased risk for the development of major stroke at one month interval.

### **One month incidence of Perforator territory stroke: (Table VI in supplement)**

Although the incidence of perforator territory stroke was higher in posterior circulation disease when compared to anterior, on multivariate analysis this risk factor did not attain statistical significance (P=0.18)

### **One year incidence of all strokes: (Table VII in supplement)**

On multivariate analysis the type of the stent i.e. the use of bare metal stent was the only factor which had significant association with the incidence of stroke in one year after the procedure (P=0.03)

### **One year Restenosis: (Table VIII in supplement)**

The use of bare metal stent (type of the stent) was the only variable that had statistically significant impact on the development of restenosis at the end of one year (P<0.00001).

## **TABLE IV:**

<b>Parameter</b>	<b>1 mth all complications</b>			
	<i>Lower 95% CI</i>	<i>OR</i>	<i>Upper 95% CI</i>	<i>p value</i>

Age	0.95	1	1.04	0.93
Sex	0.13	0.41	1.29	0.12
Hypertension	0.618	2.7	7.22	0.06
DM	0.61	2.94	7.22	0.052*
Smoking	0.16	0.5	1.53	0.22
Territory	0.34	1	2.94	0.99
Degree of stenosis	1.02	3.1	9.38	0.04*
Type of stent	0.52	1.52	4.39	0.43
Timing of procedure	0.61	2.85	7.22	0.054*

**TABLE V:**

<b>Parameter</b>	<b>I month major strokes</b>			
	<i>Lower 95% CI</i>	<i>OR</i>	<i>Upper 95% CI</i>	<i>p value</i>
Age	0	0.98	1000	0.998
Sex	0.585	3.12	16.64	0.182
Hypertension	37.11	50	65.91	<0.00001*
DM	0.143	0.764	4.05	0.751
Smoking	4.809	5.52	6.336	<0.00001*
territory	1.15	5.94	30.47	0.032*
Degree of stenosis	0.09	0.51	2.74	0.437
Type of stent	23.54	33.33	46.34	<0.00001*
Timing of procedure	16.17	25	36.9	<0.00001*

**TABLE VI:**

<b>Parameter</b>	<b>1 mth perforator stroke</b>			
	<i>Lower 95% CI</i>	<i>OR</i>	<i>Upper 95% CI</i>	<i>p value</i>
territory	0.47	4.87	49.63	0.18

**TABLE VII:**

<b>Parameter</b>	<b>1 year incidence of All strokes</b>			
	<i>Lower 95% CI</i>	<i>OR</i>	<i>Upper 95% CI</i>	<i>p value</i>
Age	0.07	0.97	1.01	0.15
Sex	-2.43	0.31	1.1	0.07
Hypertension	-1.57	0.58	1.5	0.31
DM	-1.17	0.86	0.88	0.78
Smoking	-1.66	0.63	0.74	0.45
territory	0.71	1.5	1.53	0.47
Degree of stenosis	1.03	1.12	1.18	0.95
Type of stent	1.62	4.16	10.24	0.03*
Timing of procedure	0.15	0.4	1.97	0.09

**TABLE VIII:**

<b>Parameter</b>	<b>1 year incidence of Restenosis</b>			
	<i>Lower 95% CI</i>	<i>OR</i>	<i>Upper 95% CI</i>	<i>p value</i>
Age	0	0.98	1000	0.99
Sex	0.048	0.66	9.25	0.76
Hypertension	0.023	1.36	81.01	0.88
DM	0.01	0.457	11.48	0.63
Smoking	0.027	2.27	188.45	0.71
territory	0.131	1.63	20.25	0.7
Degree f stenosis	0.041	0.27	1.79	0.17
Type of stent	37.11	50	65.91	<0.00001*
Timing of procedure	0.031	1.741	96.91	0.78



